



A Possible Solution for Women with Dense Breasts Using FMTVDM to Measure Changes in Breast Tissue

Richard M Fleming^{1*}, Matthew R Fleming¹, William C Dooley² and Tapan K Chaudhuri³

¹FHHI-Omnificimaging-Camelot, Los Angeles, CA, USA

²Oklahoma University Health Science Center, Oklahoma City, Oklahoma

³Eastern Virginia Medical School, Norfolk, VA, USA

***Corresponding Author:** Richard M Fleming, FHHI-Omnificimaging-Camelot, Los Angeles, CA, USA.

Received: November 26, 2019

Published: January 17, 2020

© All rights are reserved by **Richard M Fleming, Matthew R Fleming, William C Dooley and Tapan K Chaudhuri.**

Abstract

Background: A quantitative molecular breast imaging (MBI) utility patent (FMTVDM*), previously validated at experienced MBI centers was independently tested for clinical application at a private practice Reno, Nevada cardiologists office. Of the women studied, four were known to have dense breasts.

Methods: Using FMTVDM, a private practice cardiologist and nuclear technologist investigated four women with dense breasts, including 13-specific regions of interest (ROI). The results were compared with the mammographic and tissue findings from the medical record.

Results: Four women with dense breasts were told they had breast cancer by mammography. The medical record and measured FMTVDM found one woman had ductal carcinoma in-situ (DCIS) and another had breast cancer. Two of the four had no evidence of DCIS or cancer.

Conclusions: FMTVDM quantitative MBI measurements correctly identified the cancer and DCIS patients, while additionally correctly identifying one of the two remaining women as having inflammatory breast changes and the final woman having no evidence of inflammation or cancer. While mammography misdiagnosed 50% of the women with dense breasts, FMTVDM correctly identified the breast tissue by measuring the metabolic and regional blood flow in the breasts – correctly identifying the dense tissue as the expected normal fibro glandular tissue present in 50% of all women.

Keywords: FMTVDM; Breast Cancer; Dense Breasts; Nancy Cappello

Introduction

Qualitative mammography for screening and diagnostic purposes has proven to have little value in women with dense breasts and according to the Canadian National Breast Screening Study [1,2], provided no survival benefit for women in general. Accordingly, efforts to quantify changes in tissue associated with cancer and inflammation have resulted in the patented development of a method for quantitatively measuring changes in regional blood flow (RBF) and metabolism, associated with these different types of tissue [3-5].

Half of all women have dense breasts and it is now established that dense breasts are associated with significant mammographic errors. Following decades of state-by-state legislation, and efforts by Nancy Cappello, PhD – whose breast cancer was missed by mammography [6] – her husband Joe, and DenseBreast-info.org, the U.S. Congress passed legislation in 2019 [7] after Nancy's passing, requiring mammographic report notification of women with dense breasts, that their mammogram may miss breast cancer.

Following more than 1000 women and men previously studied using FMTVDM* [3-5], including individuals with dense breast tis-

sue, an independent, private practice cardiology site, with no prior experience in molecular breast imaging (MBI) determined if breast cancer imaging using FMTVDM could be performed by nuclear cardiologists currently conducting myocardial perfusion imaging (MPI). In this investigation, four women with dense breasts were identified and their FMTVDM results were compared with mammography results.

Methods

Patient enrollment

Of twelve women who volunteered to undergo FMTVDM – following NAS IRB and IC through Dr. David Prothro (see acknowledgment) - all previously identified as having breast irregularities, four had been identified as having dense breasts. Their mammography findings were compared with the information already known about the extent of their breast health. All components of FMTVDM are already FDA approved - including the enhancement of regional blood flow (RBF) and metabolic differences, isotopes and camera. Each woman signed an informed consent agreeing to participate in the nuclear imaging using the FMTVDM protocol. All personal identifying information was redacted to protect patient identification.

FMTVDM: Prior to imaging, the nuclear technologist, who was familiar with cardiac imaging, but unfamiliar with MBI, calibrated the Siemens' Orbiter camera according to patent instructions to guarantee quantitative calibration of the camera in addition to customary qualitative controls.

Patients arrived in the overnight fasting state and were prepared for imaging with placement of an intravenous catheter through which a vasodilator (enhancement) was given, followed by the imaging isotope as previously described [3,5].

Patient records: Patients provided inter alia detailed medical records, including prior biopsy results, mammography results, family history of cancer, any prior false positive or false negative (FPFN) results from prior testing, smoking history, current medications, or a diagnosis of dense breasts.

Measurement of Maximal Count Activity (MCA): An individual with no prior medical or technical training, received instructions on how to draw regions of interest (ROI) around the acquired breast images and obtain the measured scintillation activity used for diagnosis following completion of the imaging.

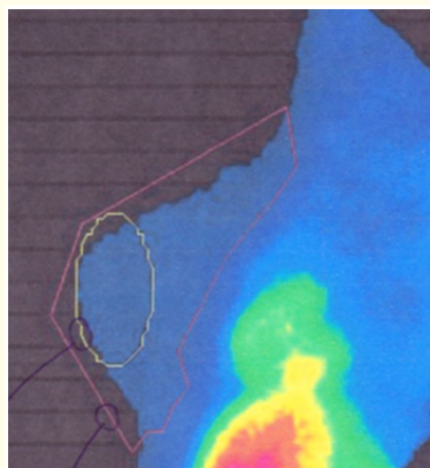
Results

The diagnostic information obtained from these 4-women included 13-regions of interest (ROI) based upon imaging and patient medical records/information. All four women had been told they had mammographic findings consistent with breast cancer. Of these four, one had ductal carcinoma in-situ (DCIS) and once had breast cancer. Two of the women had no evidence of DCIS or cancer by medical record or FMTVDM measurement.

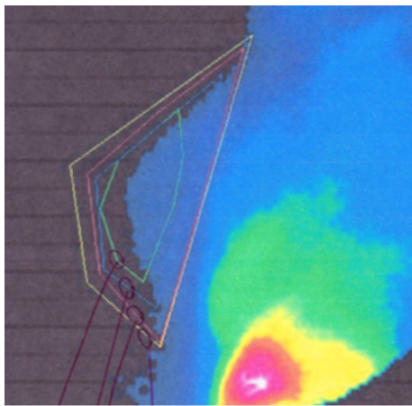
Table 1 provides specific details for each region of interest (ROI) measured, along with the breast involved. The maximal count activity (MCA) for each ROI is shown, along with tissue information, the presence or absence of breast implants, dense breasts and incorrect mammography results.

The MCAs were compared with the previously published [5] values for breast tissue including women without inflammation or cancer ($MCA 144 \pm 30$; 95% CI 138-150), women with inflammation ($MCA 229 \pm 50$; 95% CI 219 - 240) and women with breast cancer ($MCA 446 \pm 80$; 95% CI 404-489). Later research [4] showed pre-cancerous and DCIS tissue to have MCA values of 307 ± 29 ; 95% CI 270-340.


Examples of FMTVDM breast imaging are shown in figure 1, including (A) no evidence of inflammation or cancer ("normal"), (B) inflammatory changes, (C) ductal carcinoma in-situ and (D) breast cancer.



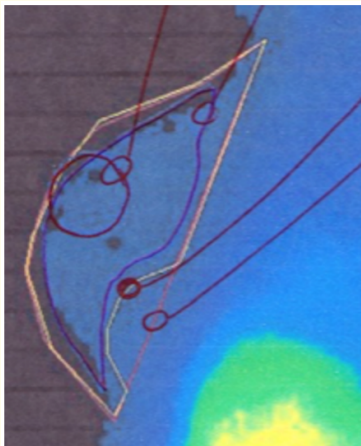
(A) – No evidence of inflammation or cancer in #2.



(B) – FMTVDM measured breast inflammation in #5.



(C) – FMTVDM measured Ductal Carcinoma In-Situ in #11.



(D) - Breast Cancer in #13.

Figure 1: Images and MCA values for normal, inflammatory, DCIS and breast carcinoma.

Initial-Breast	MCA	Tissue Data	Other
1-L	158	No CA	Dense Breasts, FP
2-L	160	No CA	Dense Breasts, FP
3-L	184	Cysts	Dense Breasts
4-R	185	No CA	Dense Breasts, FP
5-L	201	No CA	Dense Breasts, FP
6-L	203	No CA	Dense Breasts, FP
7-R	213	No CA	Dense Breasts, FP
8-R	222	No CA	Dense Breasts, FP
9-L	237	No CA	Dense Breasts, FP
10-L	259	Irregularities	Dense Breasts, Implants
11-L	264	DCIS	DCIS, Dense Breasts
12-R	290	CA with marker left	Dense Breasts, Implants
13-R	417	CA with marker left	Dense Breasts, Implants

Table 1: Patient data and diagnostic information.

FP = false positive.

Discussion

While the sample size was relatively small, it provided more than adequate information to demonstrate the applicability of FMTVDM for use in women with dense breast tissue. Of the four women, two were correctly identified by mammography as having cancer including one instance of ductal carcinoma in-situ. The remaining two cases (50%) were women with either inflammatory breast changes or no evidence of either cancer or inflammation. These mammographic findings are consistent with specificity errors reported in women with dense breasts and illustrate some of the problems associated with mammographic interpretations in women with dense breasts - which include 50% of all women.

FMTVDM measurement of metabolic and RBF differences is not influenced by dense (fibro glandular) tissue, as the measurement of this tissue, represents what is seen in normal breast tissue free of inflammation or cancer. As such, this dense tissue is measured as normal fibro glandular (dense) breast tissue.

Conclusions

While considerable debate exists as to how to address mammographic findings in women with dense breasts, FMTVDM provides at least one method for measuring the metabolism and RBF present in women with and without dense breasts. The presence of dense breasts is merely the existence of more fibro glandular supportive tissue than others. This tissue is normal and is measured as such by FMTVDM - thus providing a possible answer for women with dense breasts.

*FMTVDM = The Fleming Method for Tissue and Vascular Differentiation and Metabolism.

Acknowledgments

FMTVDM is a utility patent issued to first author. Authors MR Fleming, TK Chaudhuri and WC Dooley have no COIs. All figures reproduced with expressed consent of first author. The authors wish to thank David L Prothro, MD and his nuclear technologist of Nevada Arrhythmia Services Inc. in Reno, Nevada for independently conducting these patient studies, providing IRB and IC as well as providing the results. We would also like to dedicate this work to all the women and men with dense breasts and to Nancy and Joe Cappello.

All figures and reprinting expressly approved by first author.

Bibliography

1. Drukeinis JS, Mooney BP, Flowers CL, *et al.* "Beyond Mammography: New Frontiers in Breast Cancer Screening". *The American Journal of Medicine* 126.6 (2013): 472-479.
2. Miller AB, Wall C, Baines CJ. "Twenty five year follow-up for breast cancer incidence and mortality of the Canadian National Breast Screening Study: randomized screening trial". *British Medical Journal* 348 (2014): 366.
3. The Fleming Method for Tissue and Vascular Differentiation and Metabolism (FMTVDM) using same state single or sequential quantification comparisons (2017).
4. Fleming RM and Fleming MR. "The Importance of Thinking about and Quantifying Disease like Cancer and Heart Disease on a "Health-Spectrum" Continuum". *J Compr Cancer Rep.* 3.1 (2019):1-3.
5. Fleming RM and Dooley WC. "Breast enhanced scintigraphy testing distinguishes between normal, inflammatory breast changes, and breast cancer: a prospective analysis and comparison with mammography". *Integral Calculator Ther* 1.3 (2002): 238-245.
6. Nancy Cappello. "Breast Cancer Activist Is Dead at 66. By Denise Grady". *New York Times* (2018).
7. New federal law requires mammography providers to send breast density notifications. *Radiology Business* (2019).

Assets from publication with us

- Prompt Acknowledgement after receiving the article
- Thorough Double blinded peer review
- Rapid Publication
- Issue of Publication Certificate
- High visibility of your Published work

Website: <https://www.actascientific.com/>

Submit Article: <https://www.actascientific.com/submission.php>

Email us: editor@actascientific.com

Contact us: +91 9182824667